

Atlas of
Clinical Vascular
Medicine

Atlas of Clinical Vascular Medicine

EDITED BY

Jessica Mintz

Cleveland Clinic Heart and Vascular Institute
Cleveland Clinic Lerner College of Medicine
Case Western Reserve University
Cleveland, OH, USA

Bruce L. Mintz

Clinical Associate Professor Internal Medicine
Director Vascular Technical Training Program
University of Medicine and Dentistry of New Jersey
Newark, NJ;
Attending Gagnon Heart Center
Director Anticoagulation Service
Morristown Medical Center
Morristown, NJ, USA

Michael R. Jaff

Associate Professor of Medicine
Harvard Medical School;
Chair, MGH Institute for Heart, Vascular and Stroke Care
Massachusetts General Hospital
Boston, MA, USA

 **WILEY-BLACKWELL**

A John Wiley & Sons, Ltd., Publication

This edition first published 2013. © 2013 by John Wiley & Sons, Ltd

Wiley-Blackwell is an imprint of John Wiley & Sons, formed by the merger of Wiley's global Scientific, Technical and Medical business with Blackwell Publishing.

Registered office: John Wiley & Sons, Ltd, The Atrium, Southern Gate, Chichester, West Sussex, PO19 8SQ, UK

Editorial offices: 9600 Garsington Road, Oxford, OX4 2DQ, UK
The Atrium, Southern Gate, Chichester, West Sussex, PO19 8SQ, UK
111 River Street, Hoboken, NJ 07030-5774, USA

For details of our global editorial offices, for customer services and for information about how to apply for permission to reuse the copyright material in this book please see our website at www.wiley.com/wiley-blackwell.

The right of the author to be identified as the author of this work has been asserted in accordance with the UK Copyright, Designs and Patents Act 1988.

All rights reserved. No part of this publication may be reproduced, stored in a retrieval system, or transmitted, in any form or by any means, electronic, mechanical, photocopying, recording or otherwise, except as permitted by the UK Copyright, Designs and Patents Act 1988, without the prior permission of the publisher.

Designations used by companies to distinguish their products are often claimed as trademarks. All brand names and product names used in this book are trade names, service marks, trademarks or registered trademarks of their respective owners. The publisher is not associated with any product or vendor mentioned in this book. This publication is designed to provide accurate and authoritative information in regard to the subject matter covered. It is sold on the understanding that the publisher is not engaged in rendering professional services. If professional advice or other expert assistance is required, the services of a competent professional should be sought.

Library of Congress Cataloging-in-Publication Data

Mintz, Jessica Mintz.

p. ; cm.

Includes bibliographical references and index.

ISBN 978-0-470-65809-3 (hardback : alk. paper)

I. Mintz, Jessica. II. Mintz, Bruce L. III. Jaff, Michael R.

[DNLM: 1. Vascular Diseases--diagnosis--Atlases. 2. Vascular Diseases--diagnosis--Case Reports.

3. Vascular Diseases--therapy--Atlases. 4. Vascular Diseases--therapy--Case Reports. WG 17]

616.8'1--dc23

2012044507

A catalogue record for this book is available from the British Library.

Wiley also publishes its books in a variety of electronic formats. Some content that appears in print may not be available in electronic books.

Set in 8/12pt Stone Serif by Toppan Best-set Premedia Limited, Hong Kong

Contents

Preface and Dedication, ix

Contributor List, x

About the Companion Web Site, xii

I. Arterial Disease

Peripheral Artery Disease

1 Peripheral Artery Disease, 2
Joshua A. Beckman

2 Elevation Pallor and Dependent Rubor, 4
Ido Weinberg and Michael R. Jaff

Acute Arterial Occlusion

3 Ischemic Toes, 6
Ido Weinberg and Michael R. Jaff

4 Severe Limb Ischemia Related to Systemic Vasopressor Use, 8
Bruce L. Mintz and Michael R. Jaff

Renal Vascular Disease

5 Renal Artery Stenosis: Atherosclerotic, 10
J. Michael Bacharach

6 Renal Artery Stenosis: Fibromuscular Dysplasia, 12
J. Michael Bacharach

Arterial Dissection

7 Aortic Dissection, 14
Paul B. Haser

Carotid/Subclavian Artery Disease

8 Carotid Artery Stenosis, 16
Paul B. Haser

9 Carotid Fibromuscular Dysplasia, 18
Heather L. Gornik and Sandra Yesenko

Subclavian Artery Stenosis

10 Subclavian Artery Stenosis, 20
J. Michael Bacharach

Aneurysm

11 Abdominal Aortic Aneurysm, 22
J. Michael Bacharach

12 Popliteal Artery Aneurysm, 24
Jason Q. Alexander and Timothy Sullivan

Post-Traumatic Compartment Syndrome

13 Post-Traumatic Compartment Syndrome, 26
Ari J. Mintz and Bruce L. Mintz

Vaso-Occlusive Arterial Disease

14 Livedoid Vasculopathy, 28
Steven M. Dean

15 Digital Ischemia in Systemic Sclerosis, 30
Peter C. Grayson and Peter A. Merkel

16 Digital Arterial Thrombosis Secondary to Polycythemia Vera, 32
Jessica Mintz, John R. Bartholomew and Heather L. Gornik

Vasospastic

17 Raynaud's Phenomenon, 34
Peter C. Grayson and Peter A. Merkel

18 Acrocyanosis, 36
Ido Weinberg and Michael R. Jaff

19 Livedo Reticularis, 38
Steven M. Dean

20 Livedo Racemosa, 40
Steven M. Dean

21 Ergotism, 42
Bruce L. Mintz

Vasculitis

22 Giant Cell Arteritis (Temporal Arteritis), 44
Bruce L. Mintz

23 Polyarteritis Nodosa, 46
Peter C. Grayson and Peter A. Merkel

24 Thromboangiitis Obliterans (Buerger's Disease), 48
Raghu Kolluri

25 Small Vessel Vasculitis, 50
Peter C. Grayson and Peter A. Merkel

26 Henoch–Schönlein Purpura, 52
Shane Clark

27 Behçet's Disease, 54
Peter C. Grayson and Peter A. Merkel

28 Takayasu Arteritis, 56
Ido Weinberg and Michael R. Jaff

Vascular Anomalies

29 Marfan's Syndrome, 58
Ido Weinberg and Michael R. Jaff

30 Ehlers–Danlos Type IV (Vascular Type), 60
Bruce L. Mintz

II. Venous Disease

Deep Vein Thrombosis

31 Deep Vein Thrombosis, 62
Ari J. Mintz and Bruce L. Mintz

32 Upper Extremity Deep Vein Thrombosis, 64
Bruce L. Mintz

33 May–Thurner Syndrome, 66
Robert M. Schainfeld

34 Phlegmasia Cerulea Dolens, 68
Steven M. Dean

Anticoagulation Complications

35 Heparin-induced Thrombocytopenia, 70
Jessica Mintz, John R. Bartholomew and Heather L. Gornik

36 Warfarin-induced Skin Necrosis, 72
Bruce L. Mintz

Chronic Venous Insufficiency

37 Telangiectasias, 74
Robert M. Schainfeld

38 Reticular Veins, 76
Robert M. Schainfeld

39 Venous Varicosities, 78
Robert M. Schainfeld

Superficial Thrombophlebitis

40 Superficial Thrombophlebitis, 80
Robert M. Schainfeld

Spontaneous Venous Hemorrhage

41 Spontaneous Venous Hemorrhage (Benign Blue Finger Syndrome), 82
Bruce L. Mintz

Venous Aneurysm

42 Venous Aneurysm, 84
Bruce L. Mintz

III. Limb Edema

Lymphedema

43 Lymphedema, 86
Bruce L. Mintz

44 Milroy's Disease, 88
Jessica Mintz, John R. Bartholomew, Steven M. Dean and Heather L. Gornik

45 Filariasis, 90
Jessica Mintz, John R. Bartholomew and Heather L. Gornik

46 Yellow Nail Syndrome, 92
Bruce L. Mintz

47 Elephantiasis Nostras Verrucosa, 94
Stephen L. Chastain and Bruce H. Gray

Miscellaneous Causes of Edema

48 Lipedema, 96
Bruce L. Mintz

49 Pretibial Myxedema (Thyroid Dermopathy), 98
Steven M. Dean

50 Popliteal Cyst (Baker's Cyst), 100
Bruce L. Mintz

51 Bacterial Cellulitis, 102
Jessica Mintz, John R. Bartholomew and Heather L. Gornik

52 Gastrocnemius Muscle Rupture, 104
Bruce L. Mintz

IV. Limb Ulcerations

Venous

53 Venous Stasis Ulcer, 106
Geno J. Merli and Taki Galanis

Arterial

54 Arteriosclerosis Obliterans Ulcer (Arterial Ulcer), 108
Ari J. Mintz and Bruce L. Mintz

55 Antiphospholipid Antibody Syndrome-induced Ulceration, 110
Raghu Kolluri

56 Rheumatoid Vasculitis, 112
Cory Perugino and Raghu Kolluri

57 Calciphylaxis, 114
Jessica Mintz

58 Hypertensive Ulcer, 116
Jessica Mintz, John R. Bartholomew and Heather L. Gornik

Diabetic

59 Neurotrophic Ulcer, 118
Bruce L. Mintz

60 Necrobiosis Lipoidica Diabeticorum, 120
Raghu Kolluri

61 Deep Foot Infection, 122
Raghu Kolluri

Hematologic

62 Sickle Cell Induced Leg Ulceration, 124
Jessica Mintz, John R. Bartholomew, Michael Gironta and Heather L. Gornik

63 Thalassemia Intermedia Induced Limb Ulceration, 126
Jessica Mintz, John R. Bartholomew and Heather L. Gornik

Metabolic

64 Pyoderma Gangrenosum, 128
Ido Weinberg and Michael R. Jaff

Drugs

65 Cocaine (Levamisole) Induced Vasculitis, 130
Peter C. Grayson and Peter A. Merkel

Lichen Planus

66 Lichen Planus, 132
Georgann A. Poulos and Steven M. Dean

Brown Recluse Spider Bite

67 Brown Recluse Spider Bite, 134
Bruce L. Mintz

V. Environmental Vascular Disease

68 Frostbite, 136
Ido Weinberg, Bruce L. Mintz and Michael R. Jaff

69 Pernio (Chilblains), 138
Bruce L. Mintz

70 Trench Foot, 140
Bruce L. Mintz and Jessica Mintz

71 Erythromelalgia, 142
Bruce L. Mintz

72 Heat-induced (Cholinergic) Urticaria, 144
Joshua A. Beckman

73 Erythema Ab Igne, 146
Ido Weinberg and Michael R. Jaff

74 Hypothenar Hammer Syndrome, 148
Jessica Mintz, Heather L. Gornik and John R. Bartholomew

VI. Vascular Malformations

75 Arteriovenous Malformations, 150
Robert J. Rosen

76 Arteriovenous Fistula, 152
Robert J. Rosen

77 Pelvic Arteriovenous Malformations, 154
Robert J. Rosen

78 Pulmonary Arteriovenous Malformations, 156
Robert J. Rosen

79 Parkes–Weber Syndrome, 158
Robert J. Rosen

80 Klippel–Trenaunay Syndrome, 160
Bruce L. Mintz

81 Lymphatic Malformations, 162
Robert J. Rosen

VII. Vascular Tumors

Benign Vascular Tumors

82 Hemangioma of Infancy, 164
Jason Q. Alexander, Kate Zimmerman, Stephen C. Nelson and Timothy Sullivan

83 Kaposiform Hemangioendothelioma, 166
Robert J. Rosen

84 Glomus Tumor, 168
Robert J. Rosen

85 Angiomyolipoma, 170
Robert J. Rosen

- 86** Juvenile Nasopharyngeal Angiofibroma, 172

Robert J. Rosen

Syndrome Associated with Vascular Lesions

- 87** Maffucci's Syndrome, 174

Jessica Mintz, John R. Bartholomew and Heather L. Gornik

- 88** Osler–Weber–Rendu Syndrome, 176

*Jessica Mintz, John R. Bartholomew and
Heather L. Gornik*

Malignant Vascular Tumors

- 89** Lymphangiosarcoma, 178

Jessica Mintz, John R. Bartholomew and Heather L. Gornik

- 90** Limb Ulceration Due to Malignant Melanoma, 180

*Jessica Mintz, John R. Bartholomew and
Heather L. Gornik*

- 91** Cutaneous Waldenström's Macroglobulinemia, 182

*Jessica Mintz, John R. Bartholomew and
Heather L. Gornik*

- 92** Verrucous Carcinoma, 184

Ido Weinberg and Michael R. Jaff

VIII. Fungal Infections

- 93** Onychomycosis (Dermatophytic
Onychomycosis), 186

Bruce L. Mintz

Index, 189

Preface and Dedication

For those who have committed their professional careers to the diagnosis and management of vascular diseases, one of the true joys of this specialty is the broad and myriad presentations patients demonstrate. One can never get bored, nor can one assume that they have “seen it all”.

Vascular medicine specialists must have a keen ability to identify subtle physical diagnostic findings, and link them to often difficult historical presentations and objective imaging tests. There are many tomes on vascular medicine; however, we felt that an easy to reference pictorial atlas would serve as a useful ready reference for practicing clinicians. We have asked renowned experts in the field to help us put together a comprehensive, organized pictorial with brief descriptions of what you see in each figure. We hope you find this a useful addition to your clinical libraries.

Each of us dedicates this *Atlas* to our families, who tolerate our hectic lifestyles. Still, the true dedication of this *Atlas* is to Jess R. Young, MD, Emeritus Chair of Vascular Medicine at the Cleveland Clinic. For those of us who were privileged to train under Dr. Young (B.L.M., M.R.J.), we have never encountered his equal. Dr. Young combined a mastery of clinical medicine with an encyclopedic fund of knowledge and a unique method of approaching patients. We use Dr. Young’s approach to vascular medicine every day in our clinical practice, and attempt to pass on his acumen and diagnostic strategies to our trainees. Thank you, Dr. Young, on behalf of all of the physicians you have trained and all the patients you directly, and indirectly, touched and healed.

Contributor List

Jason Q. Alexander, MD

Assistant Professor of Clinical Surgery, University of Minnesota
Minneapolis Heart Institute, Minneapolis,
MN, USA

J. Michael Bacharach, MD, MPH, FACC, FSCAI

Section Head, Vascular Medicine and Peripheral Vascular
Intervention
North Central Heart Institute
Sioux Falls, SD, USA

John R. Bartholomew, MD

Section Head of Vascular Medicine
Cleveland Clinic Heart and Vascular Institute; Cleveland Clinic
Lerner College of Medicine of Case Western Reserve University,
Cleveland, OH, USA

Joshua A. Beckman, MD, MS

Harvard Medical School
Cardiovascular Division, Brigham and Women's Hospital
Boston, MA, USA

Stephen L. Chastain, MD

Assistant Professor of Medicine
University of South Carolina School of Medicine/Greenville;
Director of Inpatient Vascular Medicine Services
Greenville Health System, Greenville, SC, USA

Shane Clark, MD

Chief Dermatology Resident
Wexner Medical Center at the Ohio State University
Columbus, OH, USA

Steven M. Dean, DO, FACP, RPVI

Program Director, Vascular Medicine
Associate Professor of Medicine,
Department of Cardiovascular Medicine,
Wexner Medical Center at the Ohio State University
Columbus, OH, USA

Taki Galanis, MD

Assistant Professor of Medicine
Department of Surgery
Director of Hyperbaric Therapy and Wound Care
Jefferson Vascular Center
Thomas Jefferson University Hospitals
Jefferson Medical College
Philadelphia, PA, USA

Michael Girona, DO

Eastern Vascular Associates
Denville, NJ, USA

Heather L. Gornik, MD, MHS

Medical Director, Non-Invasive Vascular Laboratory
Cleveland Clinic Heart and Vascular Institute
Assistant Professor Medicine
Cleveland Clinic Lerner College of Medicine of Case Western
Reserve University
Cleveland, OH, USA

Bruce H. Gray, DO

Professor of Surgery/Vascular Medicine
University of South Carolina School of Medicine/Greenville;
Director of Endovascular Services
Greenville Health System, Greenville, SC, USA

Peter C. Grayson, MD, MSc

Assistant Professor of Medicine – Rheumatology
Vasculitis Center, Section of Rheumatology
Boston University Medical Center, Boston, MA, USA

Paul B. Haser, MD

Associate Professor of Surgery
Robert Wood Johnson Medical School
University of Medicine & Dentistry of New Jersey
New Brunswick, NJ, USA

Raghu Kolluri, MD, RVT, FACC, FACP, FSVM

Medical Director
Vascular Laboratories of Prairie Vascular Institute
Springfield, IL, USA

Peter A. Merkel, MD, MPH

Chief, Division of Rheumatology
Professor of Medicine and Epidemiology
University of Pennsylvania, Philadelphia, PA, USA

Geno J. Merli, MD, FACP, FHM, FSVM

Professor of Medicine
Co-Director, Jefferson Vascular Center,
Jefferson Medical School
Thomas Jefferson University Hospitals
Philadelphia, PA, USA

Ari J. Mintz, DO

Department of Internal Medicine
Lahey Clinic Medical Center
Burlington, MA, USA

Stephen C. Nelson, MD

Director, Hemoglobinopathy Program
Co-Director, Vascular Anomalies Clinic
Adjunct Assistant Professor
Department of Pediatrics
University of Minnesota
Children's Hospitals and Clinics of Minnesota
Minneapolis, MN, USA

Cory Perugino, DO

Cleveland Clinic Foundation
Cleveland, OH, USA

Georgann A. Poulos, MD

Wexner Medical Center at the Ohio State University
Division of Dermatology
Columbus, OH, USA

Robert J. Rosen, MD

Co-Director of Endovascular Surgery
Lenox Hill Heart and Vascular Institute
New York, NY, USA

Robert M. Schainfeld, DO

Lecturer on Medicine
Harvard Medical School
Section of Vascular Medicine
Massachusetts General Hospital, Boston,
MA, USA

Timothy Sullivan, MD

Minneapolis Heart Institute
Minneapolis, MN, USA

Sandra Yesenko, BS

Lead Technologist for Education
Non-invasive Vascular Laboratory
Cleveland Clinic
Cleveland, OH, USA

Ido Weinberg, MD MSc MHA

Vascular Medicine Section
Massachusetts General Hospital
Boston, MA, USA

Katherine P. Zimmerman

Student Research Intern
Minneapolis Heart Institute,
Minneapolis, MN, USA

About the Companion Web Site

There is a companion web site for this book at
<http://www.wiley.com/go/Jaff/Vascular>

On this site you will find

- A complete set of figures from the book

Atlas of
Clinical Vascular
Medicine

Peripheral Artery Disease

Joshua A. Beckman

Cardiovascular Division, Brigham and Women's Hospital, and Harvard Medical School, Boston, MA, USA

BRIEF CASE PRESENTATION

A 74-year-old man presents with a chief complaint of limb discomfort with exercise which resolves with rest.

CHARACTERISTICS

- Peripheral artery disease (PAD) is a common manifestation of systemic atherosclerosis
- Patients with PAD present in myriad ways. They may have no symptoms, report muscular pain with ambulation, claudication, or present with critical limb ischemia. Critical limb ischemia is represented by pain at rest, a non-healing ulcer or gangrene
- The diagnosis is made through history, careful physical examination of the lower extremities, pulse evaluation and performance of the ankle-brachial index (ABI). An ABI less than 0.91 is diagnostic of PAD
- Several other non-invasive tests are used for the diagnosis of PAD including exercise stress testing, segmental blood pressure, and pulse volume detection. Duplex ultrasonography can be utilized to pinpoint the specific morphology of the vascular lesion
- Pulse volume recordings (PVR) are especially useful in diabetic patients with non-compressible arteries as it is less effected by medial calcinosis than segmental blood pressure recordings
- Patients with PAD have a similar risk of myocardial infarction and stroke as patients with coronary heart disease, yet PAD patients are typically less intensively treated with anti-platelet therapy and risk reduction than patients with coronary disease

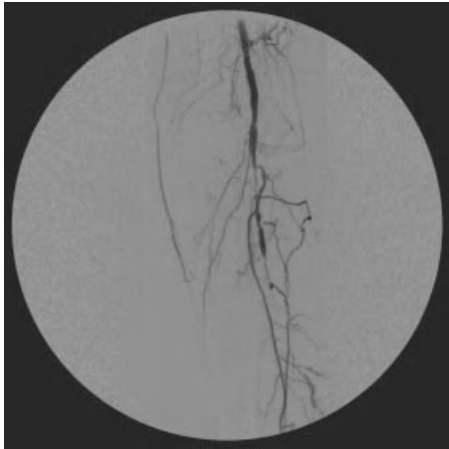
TREATMENT

Cardiovascular risk reduction therapies including tobacco cessation, blood pressure control, cholesterol management, tight glycemic control and aspirin therapy are all indicated to reduce myocardial infarction, stroke, and death. Management of intermittent claudication include risk factor intervention and a supervised exercise walking program. Revascularization is considered when medical management and maximal exercise therapy have failed to improve the patients physical functioning. In the setting of critical limb ischemia, lower extremity revascularization may be required to avoid amputation

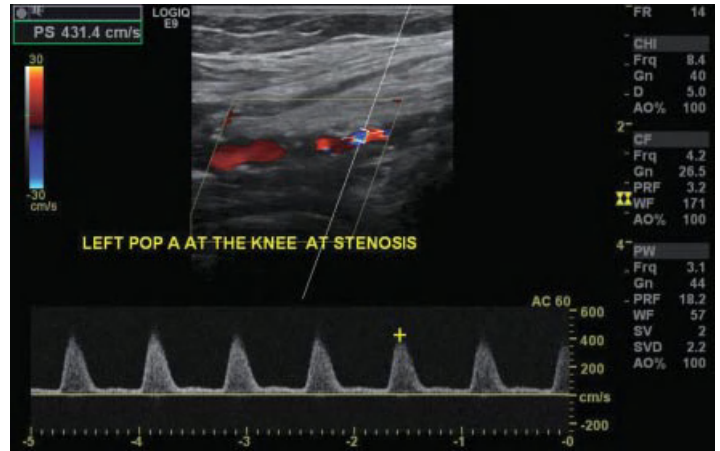
REFERENCES

- Rooke TW, Hirsch AT, Misra S, et al. ACCF/AHA 2005 Focused Update of the Guideline for the management of patients with peripheral artery disease (updating the 2005 guideline). *J Am Coll Cardiol.* 2011; 58:19.
- Hirsch AT, Criqui MH, Treat-Jacobson D, et al. Peripheral arterial disease detection, awareness, and treatment in primary care. *JAMA.* 2001; 286(11):1317–24.
- Diehm C, Allenberg JR, Pittrow D, et al. Mortality and vascular morbidity in older adults with asymptomatic versus symptomatic peripheral artery disease. *Circulation.* 2009; 120:2053–61.

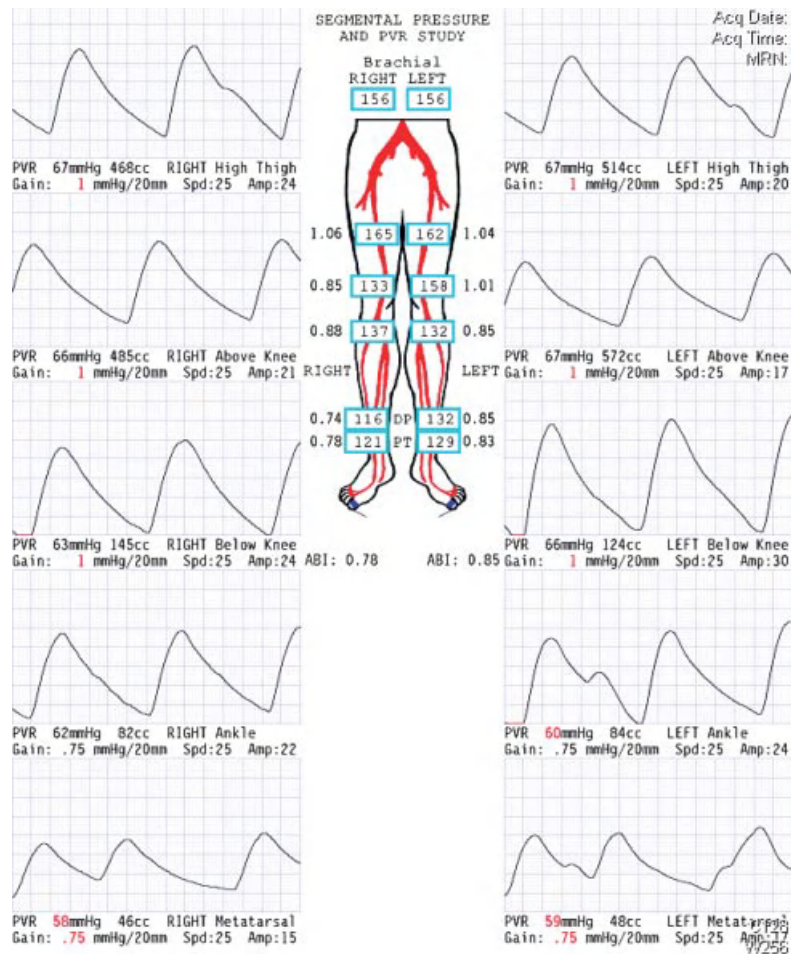
(a)



(b)



(c)



Peripheral Artery Disease Imaging. (a) Angiography of atherosclerotic popliteal artery stenosis. (b) Duplex ultrasonography of popliteal artery stenosis. (c) Pulse volume recordings demonstrating bilateral superficial femoral artery and popliteal artery stenoses.

Elevation Pallor and Dependent Rubor

Ido Weinberg and Michael R. Jaff

Massachusetts General Hospital, Boston, MA, USA

BRIEF CASE PRESENTATION

An 82-year-old woman with a history of extensive tobacco abuse and type 2 diabetes mellitus for 25 years developed foot pain during sleep. She attained relief by dangling her foot over the bed. Physical examination revealed a diminished femoral pulse and absent popliteal and pedal pulses on the right. In the dependent position, the right foot became deeply erythematous, while pallor of the forefoot developed rapidly with elevation of the foot 60 degrees above the level of the heart.

CHARACTERISTICS

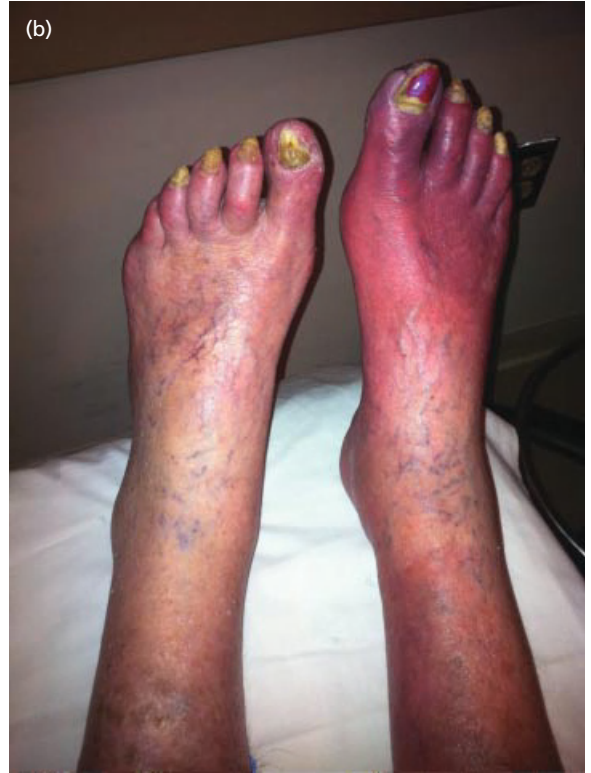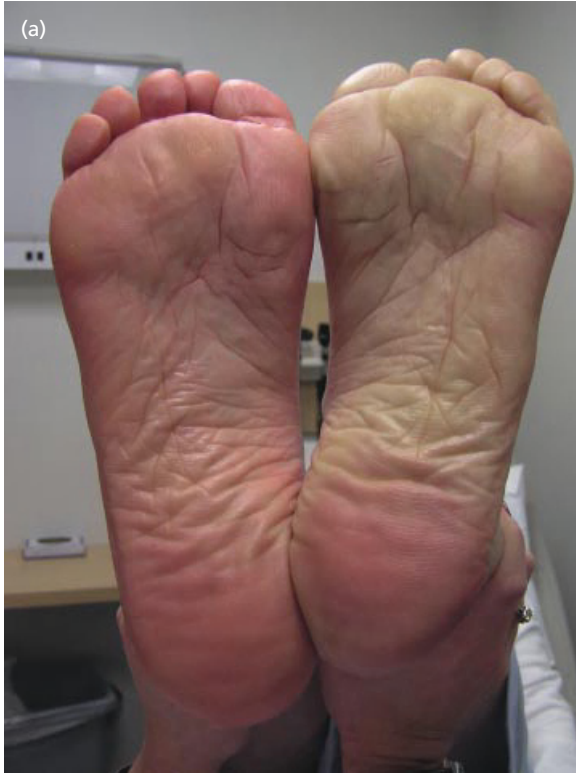- Dependent rubor and elevation pallor are elicited by the elevation-dependency test and denote severe peripheral artery disease
- Dependent rubor results from the dilation of dermal arterioles and capillaries in the presence of increased hydrostatic pressure
- Elevation pallor results from inadequate blood flow to reach the foot without the assistance of gravity

TREATMENT

This is a physical finding. Treatment must be directed towards the underlying peripheral artery disease.

REFERENCES

- Creager MA, Libby P. Peripheral arterial disease. In: Libby P, Bonow RO, Mann DL, Zipes DP. Braunwald's Heart Disease: A Textbook of Cardiovascular Medicine. 8th ed. Philadelphia, Pa: Saunders; 2007:chap 57.
- Rain, FA, Cooper LT. Peripheral arterial disease: diagnosis and management. Mayo Clinic Proceedings. 2008; 83:944–50.
- Spittell JA Jr. Occlusive peripheral arterial disease. Guidelines for office management. Postgrad Med. 1982 Feb;71(2):137–42, 146, 150–1. PubMed PMID: 6460230.



Peripheral artery examination. (a) Lower extremity demonstrating pallor on elevation. (b) Rubor on dependency.

Ischemic Toes

Ido Weinberg and Michael R. Jaff

Massachusetts General Hospital, Boston, MA, USA

BRIEF CASE PRESENTATION

A 75-year-old man presents with painful, discrete purple lesions on his toes bilaterally. Past medical history includes atrial fibrillation, hypercholesterolemia, hypertension and cigarette smoking.

CHARACTERISTICS

- Emboli to the toes cause local ischemic phenomena. They are typically intensely painful and can be located anywhere
- A bilateral lower extremity presentation suggests a central etiology such as an abdominal aortic aneurysm or cardiogenic emboli. Unilateral ischemic digits suggest a source in the extremity such as popliteal aneurysm
- Ischemic limbs can arise spontaneously or as a result of catheter manipulation
- There are multiple conditions that can mimic ischemic toes including, but not limited to, vasospastic disorders, thromboangiitis obliterans and vasculitis

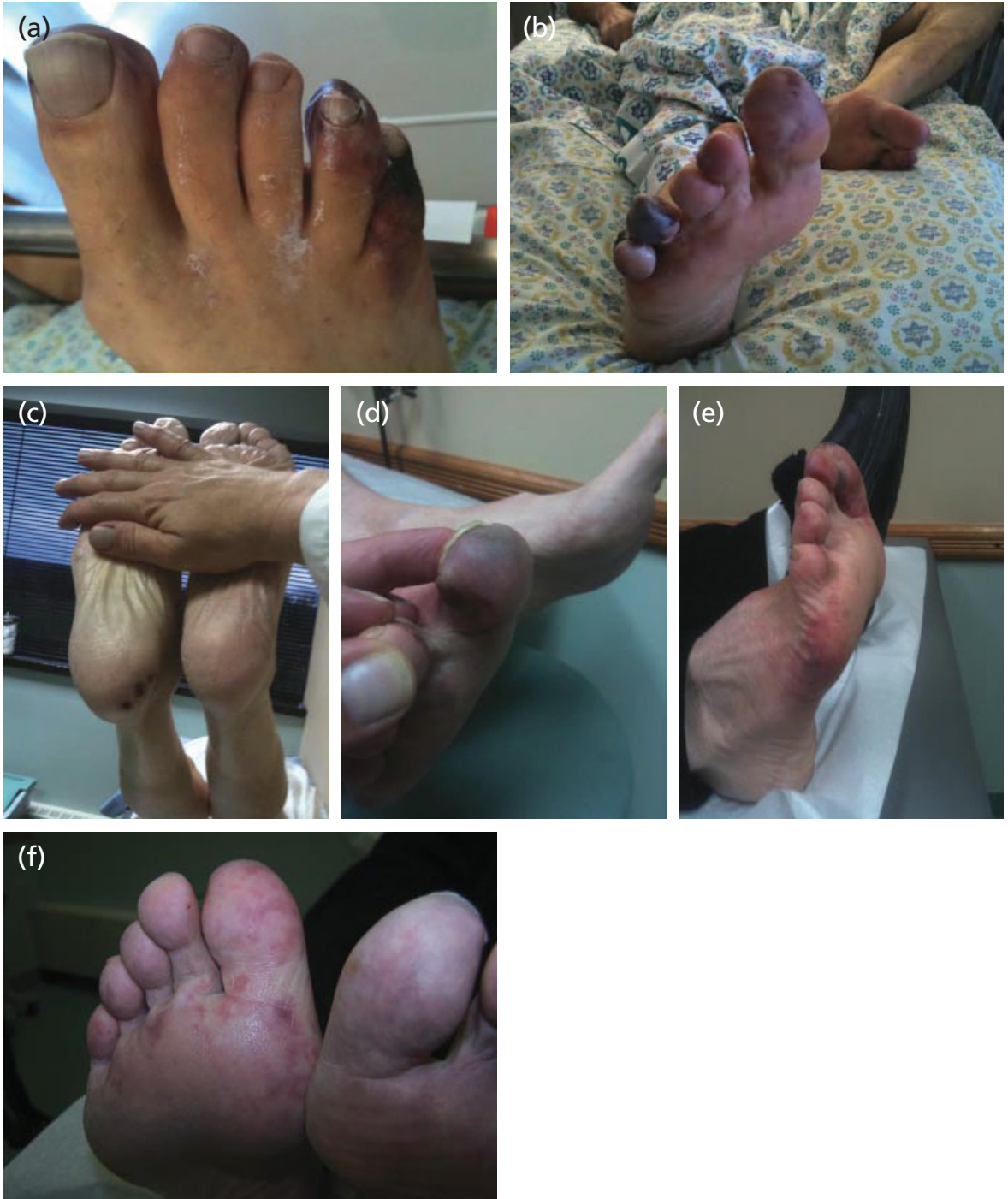TREATMENT

The specific treatment for ischemic toes includes management of pain; skin, toe, limb protection; and assessment of large artery circulation. Treatment should be

directed at the source and associated atherosclerotic risk factors. Evaluation for emboli in other vascular beds should be considered (renal, mesenteric). Systemic anti-atherosclerosis therapy should be provided.

REFERENCES

- Banerjee S, Thatthi T, Badhey N, Brilakis ES. Atheroemboli during Peripheral arterial interventions. *J Inv Cardiol.* 2009; 21(12):632–3.
- O’Keeffe ST, Woods BO, Breslin DJ, Tsapatsaris NP. Blue toe syndrome. Causes and management. *Arch Intern Med.* 1992; 152(11):2197–202.
- Richter JG, Sander O, Schneider M, Klein-Weigel P. Diagnostic algorithm for Raynaud’s phenomenon and vascular skin lesions in systemic lupus erythematosus. *Lupus.* 2010; 19(9): 1087–95. Review. PubMed PMID: 20693202.



Limb Ischemia. (a) Thromboemboli, note plethoric changes in toes along with rubor and multiple circumferential cutaneous lesions on forefoot; (b) Livedo reticularis of the great toe. Irreversible ischemia of the 4th and 5th toes. (c) Atheromatous emboli to foot with evidence of heel emboli. (d) Emboli to great toe with impending tissue loss. (e) Livedo reticularis with tissue loss of the lateral forefoot and great toe. (f) Livedo reticularis of bilateral feet. Image (c) is courtesy of Bruce L. Mintz.

Severe Limb Ischemia Related to Systemic Vasopressor Use

Bruce L. Mintz¹ and Michael R. Jaff²

¹Morristown Medical Center, Morristown, NJ, USA

²Massachusetts General Hospital, Boston, MA, USA

BRIEF CASE PRESENTATION

A 68-year-old man presented to an emergency department in cardiogenic shock. He suffered a massive anterior wall myocardial infarction and required emergency coronary artery bypass graft surgery. Due to hemodynamic instability, he required several days of vasopressor administration.

CHARACTERISTICS

- Prolonged systemic vasopressor use may result in peripheral vasoconstriction of all limbs
- Patients may develop necrosis of the tips of all digits
- These digital lesions are intensely painful and yet extremity pulses are commonly palpable
- If associated with pre-existing atherosclerosis more extensive and proximal ischemia may occur

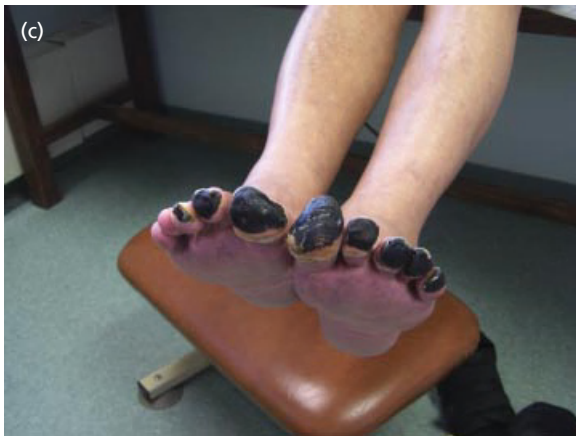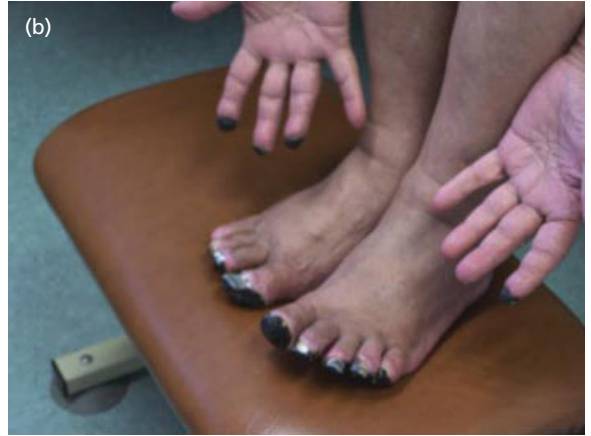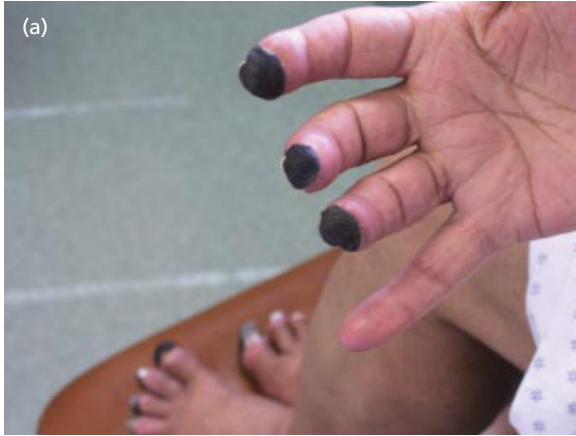TREATMENT

Cessation of vasopressor use must occur at the earliest possible moment. Analgesics for pain control as well as

protection of necrotic tissue from further trauma or infection is of paramount importance. Autoamputation is preferable, but in the case of intractable pain or infection, digital sympathectomy, botulinum toxin injection, or amputation may be considered.

REFERENCES

- Borrego R, Lopez-Herce J, Mencia S, et al. Severe ischemia of the lower limb and of the intestine associated with systemic vasoconstrictor therapy and femoral arterial catheterization. *Pediatr Crit Care Med.* 2006; 7:267–9.
- Marine L, Castro P, Enriquez A, et al. Four-limb acute ischemia induced by ergotamine in an AIDS patient treated with protease inhibitors. *Circulation.* 2011; 124:1395–7.



Vasopressor-induced limb ischemia. (a–c) Ischemic digits secondary to vasopressor agents. Images are courtesy of Dr Paul Haser.